

The Intercostal to Phrenic Nerve Transfer: An Effective Means of Reanimating the Diaphragm in Patients with High Cervical Spine Injury

Lloyd M. Krieger, M.D., M.B.A., and Abbott J. Krieger, M.D., D.M.Sc.

Los Angeles, Calif., and Livingston, N.J.

Nerve transfers have been well described for the treatment of congenital and traumatic injuries in the brachial plexus and extremities. This series is the first to describe nerve transfers to reanimate the diaphragm in patients confined to long-term positive pressure ventilation because of high cervical spine injury. Patients who have sustained injury to the spinal cord at the C3 to C5 level suffer axonal loss in the phrenic nerve. They can neither propagate a nerve stimulus nor respond to implanted diaphragmatic pacing devices (electrophrenic respiration). Ten nerve transfers were performed in six patients who met these conditions. The procedures used end-to-end anastomoses from the fourth intercostal to the phrenic nerve approximately 5 cm above the diaphragm. A phrenic nerve pacemaker was implanted as part of the procedure and was placed distal to the anastomosis. Each week, the pacemaker was activated to test for diaphragmatic response. Once diaphragm movement was documented, diaphragmatic pacing was instituted.

Eight of the 10 transfers have had more than 3 months to allow for axonal regeneration. Of these, all eight achieved successful diaphragmatic pacing (100 percent). The average interval from surgery to diaphragm response to electrical stimulation was 9 months. All patients were able to tolerate diaphragmatic pacing as an alternative to positive pressure ventilation, as judged by end tidal CO₂ values, tidal volumes, and patient comfort. Intercostal to phrenic nerve transfer with diaphragmatic pacing is a viable means of liberating patients with high cervical spine injury from long-term mechanical ventilation. (*Plast. Reconstr. Surg.* 105: 1255, 2000.)

Nerve transfers or neurotization procedures have been used successfully to treat brachial plexus injuries, to preserve muscle mass after free flaps, and to achieve facial reanimation.¹⁻⁶

These procedures have returned both sensibility and movement in selected patients. In the laboratory, nerve transfers between intercostal and distal cauda equina nerves have led to leg movement in paralyzed rats.⁷ One area in which nerve transfers hold promise but rarely have been used is in the treatment of patients confined to long-term mechanical ventilation after suffering cervical spine injuries.⁸

Patients who sustain damage at high spinal cord levels manifest respiratory insufficiency, requiring long-term mechanical ventilation. Associated morbidity is high, primarily because of respiratory complications.^{9,10} Ventilator management also requires a continuous intensive level of care and limits mobility of these already restricted patients. An established alternative to mechanical ventilation is diaphragmatic pacing (electrophrenic respiration) wherein an electrical stimulus applied to the phrenic nerve is propagated to the diaphragm and results in muscle contraction.¹¹⁻¹⁵ However, patients whose injuries involve the C3 to C5 levels are not candidates for this procedure. Because its spinal cord anterior horn cell bodies are not viable, the axons of the phrenic nerve are unable to transmit electrical stimuli. The nerve also is not able to conduct stimuli when its trunk has been directly damaged.

Several methods have been used to try to solve these problems. In cases in which the

From the Department of Surgery, Division of Plastic Surgery, UCLA Medical Center; and St. Barnabas Medical Center. Received for publication April 9, 1999; revised August 10, 1999.

Presented at the International Society of Reconstructive Microsurgery Annual Meeting, Los Angeles, California, June 22 through 26, 1999, and at the American Society for Reconstructive Microsurgery Annual Meeting, South Beach, Florida, January 8 through 11, 2000.

phrenic nerve was transected during operative procedures, successful return of diaphragmatic function has been reported both after direct reanastomosis of the nerve and with the use of an interposition sural nerve graft.^{16,17} Pacing of the intercostal muscles in addition to the phrenic nerve in patients with phrenic nerve injury has been attempted.¹⁸ Although this led to some improvement in tidal volumes, the authors concluded that it did not lead to inspired volumes sufficient to support ventilation for long periods. Combined alternating pacing of both the inspiratory and expiratory chest wall muscles in dogs has shown some promise in the laboratory.¹⁹

Nerve transfers also have been used successfully in the laboratory to achieve diaphragmatic pacing after C3 to C5 spinal cord injury. The use of brachial to phrenic nerve transfers in cats has been reported, with the subsequent institution of diaphragmatic pacing and maintenance of acceptable tidal volumes.²⁰ In this article we present the results of a similar procedure in humans, using intercostal to phrenic nerve transfers and diaphragmatic pacing to achieve reanimation of the diaphragm.

MATERIALS AND METHODS

Patient Selection

Suitable candidates for intercostal to phrenic nerve transfer have phrenic nerves

that are incapable of transmitting electrical impulses. This may be the result of direct phrenic nerve injury or of damage to the axonal cell bodies in the C3 to C5 spinal cord levels. These sorts of injuries are sometimes obvious during preoperative evaluation from the nature of the injury and from radiographic studies. Sometimes it is clear because the patient has failed to achieve diaphragmatic pacing after the surgical placement of a pacemaker. External electrical stimulation of the neck along the path of the phrenic nerve is executed to see if there is diaphragmatic response.²¹ Often, however, it is not clear which patients will benefit from nerve transfer until the phrenic nerve is directly stimulated intraoperatively. If the diaphragm responds to intraoperative stimulation, a pacemaker is placed; if it does not, a nerve transfer is performed and then a pacemaker is placed.

Surgical Procedure

Figure 1 shows the relevant surgical anatomy of the procedure. Access to the thoracic cavity is achieved with a conventional posterolateral thoracotomy through the T5 interspace. Subperiosteal dissection is used to remove the fifth rib. Obviously, care is taken not to injure the neurovascular bundle. The lung is mobilized and retracted. This maneuver is best accomplished by folding a 10-cm-wide malleable retractor into a 60-degree angle and placing it on

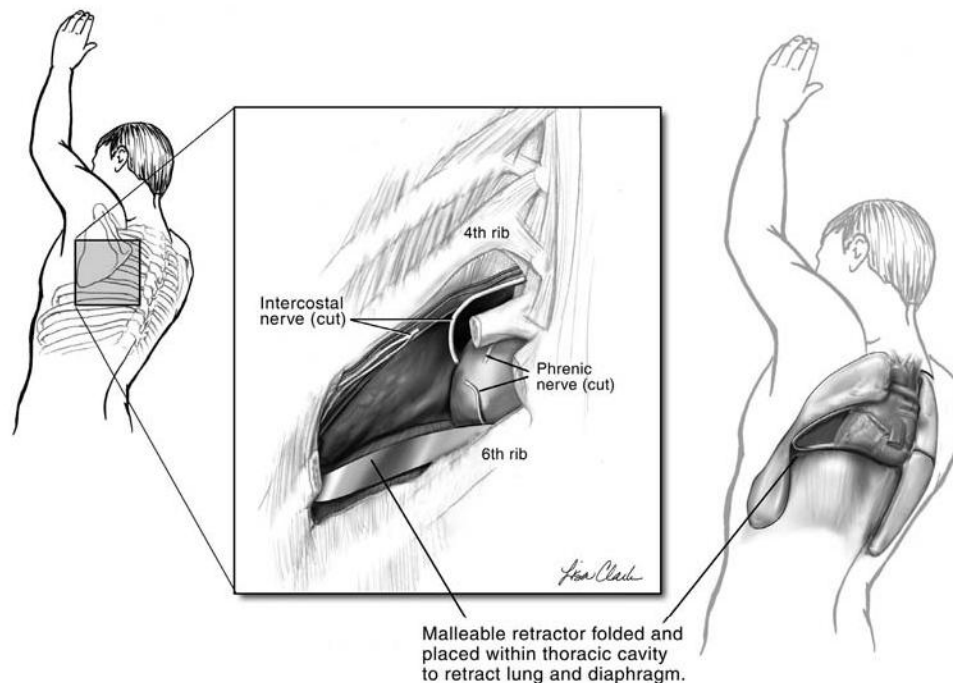


FIG. 1. Surgical anatomy of the intercostal to phrenic nerve transfer.

its side on the floor of the thoracic cavity. When positioned in this fashion, the retractor safely holds the lung at the cavity's apex and allows room for visualization and dissection without the distraction of a hand-held retractor. The phrenic nerve is located and is subjected to direct electrical stimulation to confirm diaphragmatic paralysis. A muscle pedicle is dissected overlying the neurovascular bundle. These patients are generally found to have multiple adhesions over the nerve; an external neurolysis is thus performed. Once the phrenic nerve is dissected satisfactorily, it is transected 5 cm proximal to its insertion into the diaphragm.

Next, the fourth intercostal nerve is isolated. It is dissected proximally to distally, from the spinal column to its bifurcation laterally into its two branches. The nerve thus is dissected and mobilized essentially for its entire usable length. A 5-mm cuff of surrounding tissue is left in place circumferentially around the nerve to help preserve its vascular supply. The intercostal nerve also generally has adhesions and requires external neurolysis. The nerve is transected near its distal end.

The free ends of the nerves are held in opposition, and their trunks are loosely placed along the inner wall of the thorax. It is confirmed that the anastomosis will be without any tension whatsoever, given the location of the nerves' transected ends and trunks. The intercostal nerve is then anastomosed to the phrenic nerve in an end-to-end manner by using four or five interrupted 7-0 Prolene sutures through the epineurium of the two nerves. A tongue blade is used as a stabilizer to minimize movement during the anastomosis. The actual anastomosis is done deep within the thoracic cavity and is accompanied by the constant motion of the nearby heart. For these reasons, the procedure has proved much easier to accomplish under 4.5-power loupe magnification rather than with the operating microscope.

At present, phrenic nerve pacemakers manufactured by one company are FDA-approved for use in humans (Avery Laboratories, N.Y.). The system relies on an electrode placed around the phrenic nerve and a receiver that is implanted in a nearby subcutaneous pocket. The pacemaker's monopolar electrode is applied to the phrenic nerve 1 cm distal to the anastomosis and is secured to the soft tissue of the thoracic wall by using 3-0 Prolene suture. The soft tissue surrounding the intercostal

nerve is secured to the soft tissue of the thoracic wall by using two or three superficial 5-0 Prolene sutures. A 4 by 4 cm subcutaneous pocket is created in the anterior chest wall over the ribs in the infraclavicular region, and the pacemaker's receiver is placed within it. All wounds are closed, and chest tubes are placed through the anterior chest wall to avoid possible interaction with the nerves.

Postoperative Management

After the procedure, the patient is brought to the intensive care unit for routine postoperative care. The patient usually can be discharged from the hospital about 1 week postoperatively (with a portable mechanical ventilator). Three months after surgery, the pacemaker is activated and the diaphragm is evaluated for responsiveness.

Diaphragmatic activity is evaluated by two methods: clinical and electrical. The patient is preoxygenated for 30 minutes. The patient is then taken off ventilatory support and pacing is instituted. Respiratory activity is monitored by measuring tidal volume and end tidal CO₂. Electrical activity is evaluated by assessing diaphragmatic muscle potentials in response to pacing. The pacemaker includes a feature that can send the results of this evaluation to distant locales through telephone lines.²² If the diaphragm does not respond, the patient is returned to mechanical ventilation and the diaphragm is reassessed at weekly intervals. This evaluation is repeated until the patient is noted to have sustained diaphragmatic activity. At that time a pacing schedule (without ventilator support) is instituted. The daily duration of pacing is determined by measurement of tidal volume, end tidal CO₂, and patient comfort. It is gradually increased as tolerated.

RESULTS

Table I lists the patients who underwent the nerve transfer procedure. A total of six patients were treated. Patients ranged in age from 19 to 54, with an average age of 30.3. Causes of cervical spine damage included vascular and both blunt and sharp traumatic injuries. The interval from injury to nerve transfer ranged from 6 months to 3 years, with an average of 1.7 years. Two patients underwent unilateral nerve transfer; four underwent bilateral procedures. A total of 10 nerve transfers were thus performed.

Of the six patients on whom nerve transfer was performed, five have had longer than 3

TABLE I
Summary of Nerve Transfer Patients and Results

Patient	Patient Age	Cause of Cervical Spine Injury	Interval from Injury to Nerve Transfer	Procedure	Interval from Surgery to Diaphragmatic Response to Electrical Stimulation	Current Status
1	20	Anterior spinal artery syndrome	3 years	Unilateral left NT	10 months	Capable of pacing; currently not because of depression
2	32	Spinal cord arteriovenous malformation	1 year	Unilateral left NT	9 months	Pacing 24 hours per day
3	54	Motor vehicle accident	1 year	Bilateral NT	6 months	Died of nonrespiratory causes; had been capable of pacing
4	19	Trampoline accident	3 years	Bilateral NT	7 months	Pacing 24 hours per day
5	23	Motor vehicle accident	6 months	Bilateral NT	13 months	On progressive pacing schedule
6	34	Gunshot wound	18 months	Bilateral NT	NA	One month postop; awaiting axonal regeneration

NT, nerve transfer.

months to allow for axonal regeneration. Because some of the procedures were bilateral, this is a total of eight nerve transfers. All of these nerve transfers regained diaphragmatic motion with pacing. The interval from surgery to diaphragmatic response to electrical stimulation ranged from 6 to 13 months, with an average of 9 months. Figure 2 shows a tracing of diaphragmatic muscle activity in response to

pacing of the transferred intercostal/phrenic nerve. It demonstrates biphasic muscle potentials.

The current status of these five eligible patients includes two who are completely free of ventilatory support and are pacing 24 hours per day. One patient recently developed diaphragmatic response to pacing and has begun a progressive daily pacing schedule. Another

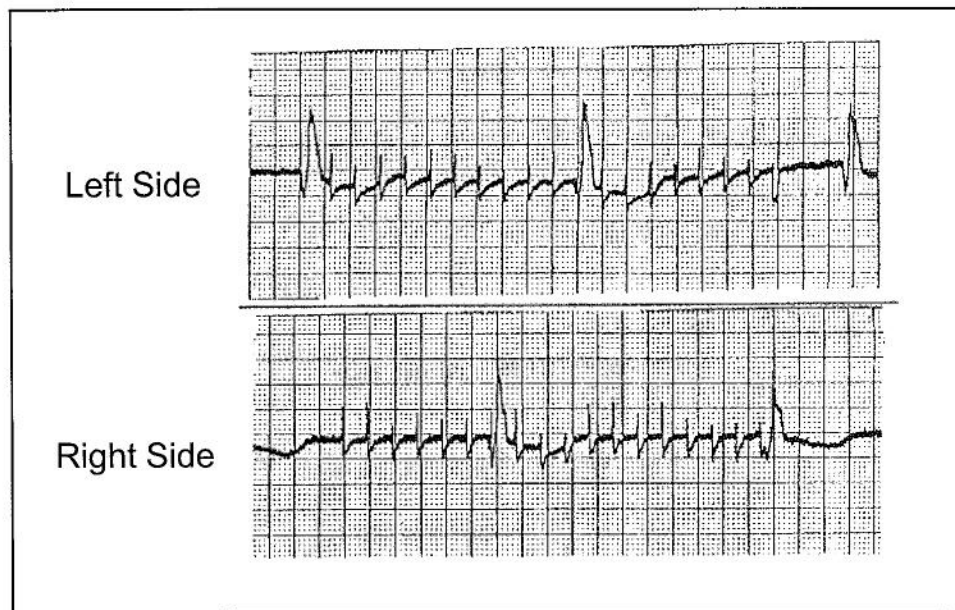


FIG. 2. Tracing showing biphasic diaphragmatic response to electrical stimulation. This patient underwent bilateral nerve transfers 17 months previously and, at the time of this study, was using his diaphragmatic pacemaker rather than mechanical ventilation for 24 hours per day. He generated tidal volumes of 600 to 800 cc.

patient is able to use the pacemaker, but a recent depression has left him frustrated with his overall condition and he currently chooses to remain on the ventilator. The last patient died of nonrespiratory causes approximately 8 months postoperatively but had regained bilateral diaphragm movement with pacing before that time.

DISCUSSION

The phrenic nerve is formed from the ventral rami of C3 to C5 with the primary contribution coming from C4. These roots unite and descend almost vertically to the diaphragm, where the nerve then divides into three phrenico-abdominal branches, supplying the diaphragm from its inferior surface.^{23,24} Physiologically, the loss of these fibers is devastating inasmuch as the paired phrenic nerves are the only nerves that provide motor stimuli to the diaphragm. If an individual sustains an injury above the C3 spinal cord level, the diaphragm will be paralyzed. In this case, the phrenic nerves themselves will remain viable because the anterior horn cells are intact. Such patients are candidates for conventional diaphragmatic pacing. However, if the injury involves the anterior horn cells of C3 to C5, the cell bodies are destroyed and Wallerian degeneration leads to axonal loss in the phrenic nerves. The nerves cannot propagate electrical impulses, and patients with these injuries are not candidates for diaphragmatic pacing. These patients are generally confined to long-term mechanical ventilation. Patients who suffer iatrogenic injury to the phrenic nerve often face a similar fate. If the nerve is transected and not repaired soon after injury, its ends can become adhered to the surrounding tissue; this can make direct repair and, sometimes, interposition grafting impossible. Permanent phrenic nerve dysfunction can also result from cold cardioplegia solution during cardiac surgery.²⁵⁻²⁷

Surgical remedies have been used in some cases of phrenic nerve injury.¹⁶⁻¹⁹ The senior author performed brachial to phrenic nerve transfers in cats and used diaphragmatic pacing to achieve successful diaphragmatic pacing in cats.²⁰ This investigative work indicated that nerve transfers seemed to offer a means of achieving diaphragmatic reanimation in humans.

The intercostal nerve was chosen as the donor for this procedure on both anatomic and physiologic grounds. The proximity of the in-

tercostal nerves to the phrenic nerve and its insertion into the diaphragm allow convenient surgical exposure and a short course of axonal regeneration. The intercostal and phrenic nerves have similar functions in that their motor neurons are involved in respiration. Both innervate skeletal muscle and release acetylcholine as their neurotransmitter; also, the nerves are of similar size. The fourth intercostal nerve is used because it reaches the phrenic nerve most easily. Attempts with the seventh intercostal nerve have proved less facile because it is located below the horn of the diaphragm; its cut end reached that of the phrenic nerve only with some degree of tension at the anastomosis.

Cervical nerves below the site of injury also seem appealing as donors for the nerve transfer. In cases of high cervical spine injury, the anterior horn cells remain viable at cord levels below the site of injury. These cells can propagate a nerve stimulus, but they do not do so in an orderly fashion because they are disconnected from the higher nervous system. (This is why paraplegic patients often suffer lower extremity spasticity: their nerves function, but they do so in a disorganized way.) A nerve transfer of one of these nerves to the phrenic nerve with pacing might solve these problems while sparing patients the added morbidity of a thoracotomy. However, a high anastomosis means that growing nerve stumps must traverse a larger distance to reach the diaphragm. Moreover, external stimulation is not foolproof in assessing the viability of phrenic nerves.²⁸ Three of the patients in this series initially were thought to need bilateral nerve transfer procedures because external stimulation yielded no diaphragmatic response. At the time of surgery, however, the phrenic nerve on one side responded to direct stimulation. These patients simply received a pacemaker to those responsive sides and were spared unnecessary transection of viable phrenic nerves. On the basis of these experiences, direct visualization of diaphragmatic activity seems prudent before cutting the phrenic nerve.

This series shows positive results from intercostal to phrenic nerve transfers in human quadriplegic patients with C3 to C5 spinal cord lesions. A total of 10 nerve transfers were performed, of which eight have had sufficient time for axonal regeneration at the time of this report. All eight of these nerve transfers led to diaphragmatic motion when the combined in-

tercostal/phrenic nerve was stimulated by a diaphragmatic pacemaker. A total of six patients underwent the procedure; at the time of this report, five have had sufficient time for axonal regeneration. Two of the five patients are completely liberated from mechanical ventilation. One patient recently began a progressive pacing schedule. Another patient is physiologically capable of diaphragmatic pacing but chooses not to do so because of psychiatric issues. The final patient died but had demonstrated successful diaphragmatic pacing before his demise.

The timing of reconstructive surgery after injury is an important issue in all muscle reanimation procedures. Classic work focusing on facial muscle reanimation has led many to conclude that in cases of complete muscle denervation, surgical interventions should be performed within 2 years of injury.^{29,30} One of the patients presented here had sustained his injury 3 years before the nerve transfer procedure. He regained diaphragmatic motion after the nerve transfer, and, perhaps coincidentally, did so in the shortest amount of time after the procedure. It is possible that the large muscles of the diaphragm may undergo a somewhat different pattern and timing of degeneration after denervation than the small muscles in the face. Another explanation for the ability to achieve axonal growth in the distal phrenic nerve so long after injury may involve incomplete injury at the C3 to C5 levels. This would preserve some anterior horn cells and their axons. These cells would not be sufficient to create observable diaphragmatic response on their own or with intraoperative electrical stimulation. However, the intact anterior horn cells might provide viable axons, which, after the nerve transfer and pacing, allow for electrophrenic respiration.

The accepted growth rate of regenerating axons is 1 mm per day.³¹ Because our anastomoses were 5 cm from the diaphragm, we would expect regeneration to occur within 50 days, perhaps with a 1- to 2-month latency period. In no case did diaphragmatic reanimation follow this schedule. The most rapid return of diaphragmatic response to electrical stimulation was 6 months and the longest was 13 months, with an average of 9 months. Perhaps the large diaphragm muscles require a longer latency period than the smaller muscles in the upper extremity and face. Or, perhaps

the large-caliber phrenic nerve requires longer than the accepted upper extremity nerve axonal growth rate of 1 mm per day.

Lastly, peripheral nerve surgery within a body cavity poses unique challenges. Several technical points are worthy of comment. All manipulations of peripheral nerves and nerve transfer procedures involve a balance between adequate dissection and mobilization of the nerve trunk and maintenance of the nerve's blood supply.³²⁻³⁴ Extensive mobilization helps to create anastomoses with minimal tension but may harm the blood supply of the nerve. Minimal mobilization maximally preserves vascularity but may lead to tension at the anastomosis. In the intercostal to phrenic nerve transfer, we believe that adequate mobilization is of paramount importance. We dissect and mobilize the intercostal nerve for essentially its entire length. This allows an anastomosis without any tension whatsoever. More limited mobilization procedures have not proved satisfactory in this regard. Attempts are made to maintain nerve vascularity by including a generous cuff of tissue around both nerves and then, following the anastomosis, securing the nerves to the vascular tissue of the inner thoracic wall.

Both the dissection of the nerves and anastomosis itself have proved troublesome under the operating microscope. The dissections are along angles difficult to keep in focus. Even with the nerves well mobilized, the anastomosis must be performed deep in the thoracic cavity. Also, the constantly beating heart agitates the small operative field as viewed under high-power magnification. The use of 4.5-power loupes allows for excellent visualization of the relatively large nerves as well as better orientation as one attempts to place sutures through the epineurium of deep and constantly moving targets.

CONCLUSIONS

Recent advances in microsurgical technique and understanding of axonal physiology have allowed new procedures for achieving muscle reanimation. The intercostal to phrenic nerve transfer is an example of these new procedures. When combined with diaphragmatic pacing, it has proved useful in the reanimation of the diaphragm for patients suffering C3 to C5 spinal cord injuries.

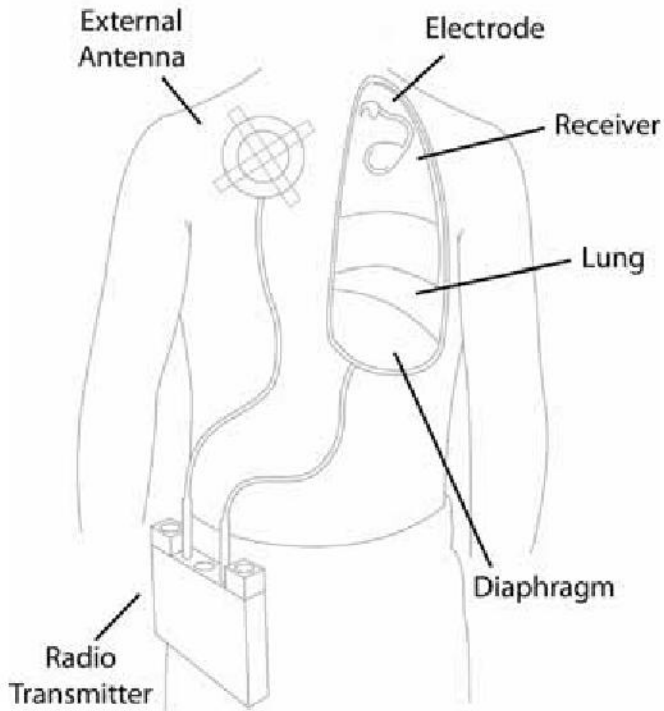
Lloyd M. Krieger, M.D., M.B.A.
 Division of Plastic Surgery
 UCLA Medical Center
 10833 Le Conte Avenue
 Los Angeles, Calif. 90095
 lkrieger@ucla.edu

REFERENCES

- Tomita, Y., Tsai, T. M., Burns, J., et al. Intercostal nerve transfer in brachial plexus injuries: An experimental study. *Microsurgery* 4: 95, 1983.
- Nagano, A., Tsuyama, N., Ochiai, N., et al. Direct nerve crossing with the intercostal nerve to treat avulsion injuries of the brachial plexus. *J. Hand Surg.* 14A: 980, 1989.
- Chuang, D. C. Neurotization procedures for brachial plexus injuries. *Hand Clin.* 11: 633, 1995.
- Zhang, F., Lineaweaver, W. C., Ustuner, T., et al. Comparison of muscle mass preservation in denervated muscle and transplanted muscle flaps after motor and sensory reinnervation and neurotization. *Plast. Reconstr. Surg.* 99: 803, 1997.
- May, M. Facial paralysis: Differential diagnosis and indications for surgical therapy. *Clin. Plast. Surg.* 6: 275, 1979.
- Chency, M. L., McKenna, M. J., Megerian, C. A., West, C., and Elahi, M. M. Trigeminal neo-neurotization of the paralyzed face. *Ann. Otol. Rhinol. Laryngol.* 106: 733, 1997.
- Zhao, S., Beuerman, R. W., and Kline, D. G. Neurotization of motor nerves innervating the lower extremity by utilizing the lower intercostal nerves. *J. Reconstr. Microsurg.* 13: 39, 1997.
- Krieger, A. J., Gropper, M. R., and Adler, R. J. Electrophrenic respiration after intercostal to phrenic nerve anastomosis in a patient with anterior spinal artery syndrome: Technical case report. *Neurosurgery* 35: 760, 1994.
- Apple, D. F. Spinal Cord Injury Rehabilitation. In R. H. Rothman and F. A. Simeone (Eds.), *The Spine*. Philadelphia: Saunders, 1992. Pp. 1225-1246.
- Mesard, L., Carmody, A., Mannarino, E., and Ruge, D. Survival after spinal cord trauma. *Arch. Neurol.* 35: 78, 1978.
- Glenn, W. W., and Phelps, M. L. Diaphragm pacing by electrical stimulation of the phrenic nerve. *Neurosurgery* 17: 974, 1985.
- Moxham, J., and Shneerson, J. M. Diaphragmatic pacing. *Am. Rev. Respir. Dis.* 148: 533, 1993.
- Glenn, W. W., Phelps, M. L., Eleftheriades, J. A., Dentz, B., and Hogan, J. F. Twenty years experience in phrenic nerve stimulation to pace the diaphragm. *Pacing Clin. Electrophysiol.* 9: 780, 1986.
- Chervin, R. D., and Guilleminault, C. Diaphragm pacing: Review and reassessment. *Sleep* 17: 176, 1994.
- Tibballs, J. Diaphragmatic pacing: An alternative to long-term mechanical ventilation. *Anaesth. Intensive Care* 19: 597, 1991.
- Brouillette, R. T., Hahn, Y. S., Noah, Z. L., Ilbawi, M. N., and Wessel, H. U. Successful reinnervation of the diaphragm after phrenic nerve transection. *J. Pediatr. Surg.* 21: 63, 1986.
- Merav, A. D., Attai, L. A., and Condit, D. D. Successful repair of a transected phrenic nerve with restoration of diaphragmatic function. *Chest* 84: 642, 1983.
- DiMarco, A. F., Supinski, G. S., Petro, J. A., and Takaoka, Y. Evaluation of intercostal pacing to provide artificial ventilation in quadriplegics. *Am. J. Respir. Crit. Care Med.* 150: 934, 1994.
- DiMarco, A. F., Romaniuk, J. R., Kowalski, K. E., and Supinski, G. S. Efficacy of combined inspiratory intercostal and expiratory muscle pacing to maintain artificial ventilation. *Am. J. Respir. Crit. Care Med.* 156: 122, 1997.
- Krieger, A. J., Danetz, I., Wu, S. Z., Spatola, M., and Sapru, H. N. Electrophrenic respiration following anastomosis of phrenic with brachial nerve in the cat. *J. Neurosurg.* 59: 262, 1983.
- Meir, A., Brophy, C., Moxham, J., and Green, M. Phrenic nerve stimulation in normal subjects and in patients with diaphragmatic weakness. *Thorax* 42: 885, 1987.
- Auerbach, A. A., and Dobbelle, W. H. Transtelephonic monitoring of patients with implanted neurostimulators (Letter). *Lancet* 1: 224, 1987.
- Merendino, K. A., Johnson, R. J., Skinner, H. H., et al. The intradiaphragmatic distribution of the phrenic nerve with particular reference to the placement of diaphragmatic incisions and controlled segmental paralysis. *Surgery* 39: 189, 1956.
- Brass, A. B., and Dingle, R. V. The Nervous System. In F. H. Netter (Ed.), *The Ciba Collection of Medical Illustrations*, Vol. 1. West Caldwell, N.J.: Ciba Pharmaccuticals Co., 1986. Pp. 114-115.
- DeVita, M. A., Robinson, L. R., Rehder, J., Hattler, B., and Cohen, C. Incidence and natural history of phrenic neuropathy occurring during open heart surgery. *Chest* 103: 850, 1993.
- Diehl, J., Lofaso, F., Deleuze, P., Similowski, T., Lemaire, F., and Brochard, L. Clinically relevant diaphragmatic dysfunction after cardiac operations. *J. Thorac. Cardiovasc. Surg.* 107: 487, 1994.
- Efthimiou, J., Butler, J., Woodham, C., et al. Diaphragm paralysis following cardiac surgery: Role of phrenic nerve cold injury. *Ann. Thorac. Surg.* 52: 1005, 1991.
- Shaw, R. K., Glenn, W. W., Hogan, J. F., and Phelps, M. L. Electrophysiological evaluation of phrenic nerve function in candidates for diaphragm pacing. *J. Neurosurg.* 53: 345, 1980.
- Patel, A. N., Razzak, Z. A., and Dastur, D. K. Disuse atrophy of human skeletal muscles. *Arch. Neurol.* 20: 413, 1969.
- Terzis, J. K. *Microreconstruction of Nerve Injuries*. Philadelphia: Saunders, 1987.
- Mackinnon, S. E., and Dellon, A. L. *Surgery of the Peripheral Nerve*. New York: Thieme Medical Publishers, 1981.
- Breidenbach, W. C., and Terzis, J. K. Vascularized nerve grafts: An experimental and clinical review. *Ann. Plast. Surg.* 18: 137, 1987.
- Maki, Y., Firrell, J. C., and Breidenbach, W. C. Blood flow in mobilized nerves: Results in a rabbit sciatic nerve model. *Plast. Reconstr. Surg.* 100: 627, 1997.
- Terzis, J. K., and Smith, K. L. *The Peripheral Nerve: Structure, Function, and Reconstruction*. Norfolk, Va.: Hampton Press, 1990.

Bibliography

1. Khong P, Lazzaro A, Mobbs R. "Phrenic Nerve Stimulation: The Australian Experience." *Journal of Clinical Neuroscience*. Vol. 17, No. 2, February 2010, pp. 205-208.
2. Surani SR, Ayala EE, McMillian M, Sablonte E, Acosta A. "Long Term Recovery of Diaphragmatic Function in a Patient with Unilateral Diaphragm Pacemaker." *Current Respiratory Medicine Reviews*. Vol. 5, No. 1, February 2009, pp. 59-61.
3. Hirschfeld S, Exner G, Luukkaala T, Baer GA. "Mechanical Ventilation or Phrenic Nerve Stimulation for Treatment of Spinal Cord Injury-Induced Respiratory Insufficiency." *Spinal Cord*. Advance online publication May 13, 2008.
4. Eleftheriades JA, Quin JA, Hogan JF, Holcomb WG, Letsou GV, Chlosta WF, Glenn WW. "Long-Term Follow-up of Pacing of the Conditioned Diaphragm in Quadriplegia." *Journal of Pacing and Clinical Electrophysiology*. Vol. 25, No. 6, June 2002, pp. 897-906
5. Shaul DB, Danielson PD, McComb JG, Keens TG. "Thorascopic Placement of Phrenic Nerve Electrodes for Diaphragm Pacing in Children." *Journal of Pediatric Surgery*. Vol.37, No.7 (July 2002), pp.974-978.
4. Chen ML, Tablizo MA, Kun S, Keens TG. "Diaphragm Pacers as a Treatment for Congenital Central Hypoventilation Syndrome." *Expert Review of Medical Devices*. Vol. 2, No. 5, May 2005, pp. 577-585
6. Kolb C, Eicken A, Zrenner B, Schmitt C. "Cardiac Pacing in a Patient with Diaphragm Pacing for Congenital Central Hypoventilation Syndrome (Ondine's Curse)" *Journal of Cardiovascular Electrophysiology*. Vol. 17, No. 7, July 2006, pp. 1-3.
7. Argenziano, M et al. "Endoscopic, Robotically Assisted Implantation of Phrenic Pacemakers." *The Journal of Thoracic and Cardiovascular Surgery*. Vol.126, No. 2, August 2003, pp. 582-583.
8. Krieger L, Krieger A. "The Intercostal to Phrenic Nerve Transfer: An Effective Means of Reanimating the Diaphragm in Patients with High Cervical Spine Injury." *Plastic and Reconstructive Surgery*. April 2000, pp. 1255-1261.



The external transmitter and antennas transmit energy to the bilaterally implanted receivers, which convert the radio signals into stimulating pulses delivered to both phrenic nerves by the electrodes.

The hemidiaphragms then contract, producing inhalation. The train of impulses then stops, allowing the diaphragm to relax, and exhalation to occur. Cyclic repetition of pulse trains, followed by no pulses, produces a normal breathing pattern. Some of the earliest patients have been pacing for more than 30 years, and many for more than two decades.

Refer to the instruction manual, which is provided with each device, for detailed instructions for use, warnings, precautions, and adverse side effects. Federal law (USA) restricts this device to sale by or on the order of a physician.

Avery Biomedical Devices, Inc.

61 Mall Drive

Commack, NY 11725-5703

Phone: 631-864-1600, Fax: 631-864-1610

www.averybiomedical.com