

## **Endoscopic, robotically assisted implantation of phrenic pacemakers**

Jeffrey A. Morgan, MD,<sup>a</sup> David L. Morales, MD,<sup>a</sup> Ranjit John, MD,<sup>a</sup> Mark E. Ginsburg, MD,<sup>b</sup> Aftab R. Kherani, MD,<sup>a</sup> Deon W. Vigilance, MD,<sup>a</sup> Faisal H. Cheema, MD,<sup>a</sup> Craig R. Smith, Jr, MD,<sup>a</sup> Mehmet C. Oz, MD,<sup>a</sup> and Michael Argenziano, MD,<sup>a</sup> New York, NY

**D**iaphragmatic pacing is a technique that was pioneered by Dr William Glenn, who began clinical experiments in 1966 and reported his experience in 1968.<sup>1</sup> It is most commonly performed for patients with quadriplegia and central alveolar hypoventilation. Phrenic pacing can eliminate the requirement for ventilatory support.<sup>2,3</sup> Other indications include intractable hiccups (singultus) and phrenic nerve injury.

This procedure is typically performed with an open technique through a cervical approach requiring multiple neck incisions, a thoracic approach requiring multiple bilateral 5- to 7-cm anterior thoracotomy incisions, or a sternotomy.<sup>4</sup> An endoscopic approach minimizes the number and size of incisions to three 1-cm incisions. In the thorax, the phrenic nerve is a continuous single trunk. With a thoracic approach, full potential of phrenic nerve stimulation can be achieved.

### **Patients and Methods**

During the course of 1 year, 6 patients underwent implantation of phrenic nerve pacemakers (Avery Laboratories, Dobelle Institute, Commack, NY) through an endoscopic approach with robotic assistance. Mean age was  $40.2 \pm 24.2$  years (range 16-81 years), with 3 male and 3 female patients. The indications were quadriplegia ( $n = 2$ ), central hypoventilation syndrome ( $n = 2$ ), and intractable hiccups ( $n = 2$ ). Informed consent was obtained from each patient.

**Surgical procedure.** The Da Vinci robotic system (Intuitive Surgical, Mountain View, Calif) consists of a surgeon's control console along with a surgical arm unit that positions and maneuvers detachable surgical instruments. From the console, the surgeon has a 3-dimensional, magnified, stereoscopic view of the operative field. The surgeon telemanipulates the two "master" handles, which are positioned beneath the console. The wrists of the robot mimic the motions made by the surgeon.

The first 1-cm incision is made in the 4th intercostal space, 2 cm anterior to the anterior axillary line. The robotic endoscopic camera, which is attached to a fiberoptic cable, is inserted, and entry into the pleural space is confirmed. Two additional 1-cm incisions, through which the right and left arms of the robotic system are inserted sequentially under direct videoscopic guidance, are made in the 2nd and 6th intercostal spaces (Figure 1).

The surgeon dissects a small segment of the left phrenic nerve free from the pericardium. The pacing lead is positioned around the nerve and affixed to the pericardium (Figure 2). On the left the implantation site is at the level of the left pulmonary artery, whereas on the right it is at the confluence of the superior vena cava and right atrium. The lead is passed through the robotic arm trocar site and attached to the receiver, which is implanted in a small subcutaneous pocket. The pacer is tested for proper function.

**Postoperative management.** Pacing is usually not begun until 28 days after the operation, to allow edema and inflammation to subside. The patient is then studied under fluoroscopic guidance. The pacemaker is tested and its settings are adjusted. The threshold necessary to generate diaphragmatic excursion is recorded. Spirometric values are calculated, along with arterial blood gas values. Adjustments are made in current amplitude, pulse interval, and respiratory rate. The goal is to maximize respiration with the least amplitude required for diaphragmatic contraction.<sup>5</sup>

From the Department of Surgery, Division of Cardiothoracic Surgery,<sup>a</sup> and the Department of Surgery, College of Physicians and Surgeons,<sup>b</sup> Columbia University, New York, NY.

Received for publication Dec 11, 2002; revisions requested Dec 30, 2002; revisions received Jan 16, 2003; accepted for publication Feb 11, 2003.

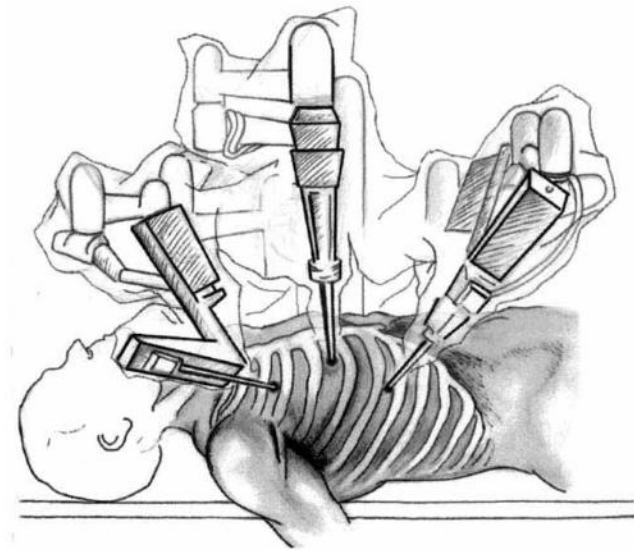
Address for reprints: Jeffrey A. Morgan, MD, Columbia University, College of Physicians and Surgeons, 177 Fort Washington Ave, Room 17-415, New York, NY 10032 (E-mail: Jm2240@columbia.edu).

J Thorac Cardiovasc Surg 2003;126:582-3

Copyright © 2003 by The American Association for Thoracic Surgery

0022-5223/2003 \$30.00 + 0

doi:10.1016/S0022-5223(03)00721-9



**Figure 1. Patient placement on operating table and port positions.**

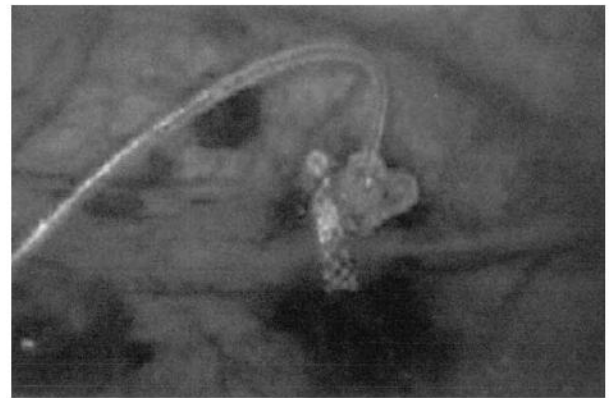### Results

Phrenic pacemakers were successfully implanted through an endoscopic approach with robotic assistance in all 6 patients. In 5 patients, a single-staged bilateral procedure was performed; in 1 patient, a two-staged unilateral procedure was pursued. There were no conversions to open procedures. Total operative time ranged from 80 to 120 minutes. There were no intraoperative complications. In 5 patients, effective pacing was confirmed during the operation. In 1 patient, testing after 3 weeks confirmed effective pacing. There were no postoperative complications or deaths. Hospital stay was  $1.7 \pm 1.0$  days.

Mean follow-up was  $258.3 \pm 176.3$  days. There were no device malfunctions or mechanical difficulties. One quadriplegic patient has been rendered free of the need for a ventilator during the day. The other quadriplegic patient is free of the need for a ventilator for 4 to 5 hours each day. One of the patients with central hypoventilation syndrome is free of the need for a ventilator approximately 50% of nights, whereas the other has not yet begun pacing. One of the patients with singultus has had significant improvement in symptoms.

### Discussion

Phrenic nerve pacing can improve quality of life in quadriplegic patients and in patients with primary alveolar hypoventilation by eliminating the dependence on a ventilator. In patients with per-



**Figure 2. Pacing lead secured around phrenic nerve.**

sistent or intractable hiccups, phrenic pacing can significantly affect general health through improvements in eating, sleeping, and drinking.<sup>5</sup>

Insertion of a phrenic pacemaker through an endoscopic approach with robotic assistance minimizes surgical trauma. By avoiding multiple neck incisions, bilateral thoracotomies, or a sternotomy, an endoscopic approach is likely to yield a hastened postoperative recovery and improved quality of life. Although a standard thoracoscopic approach may be used to perform this procedure, a specialized skill set is required. The use of robotic technology allows this relatively challenging thoracoscopic procedure to be performed easily by surgeons with little thoracoscopic experience. Certainly the additional cost of this technology needs to be factored into an analysis of the overall benefit derived from this approach. We are currently conducting studies on quality of life and cost to further address these issues.

### References

1. Judson JP, Glenn WL. Radiofrequency electrophrenic respiration: long-term application to a patient with primary hypoventilation. *JAMA*. 1968;203:1033-7.
2. Miller JJ, Farmer JA, Stuart W, Apple D. Phrenic nerve pacing of the quadriplegic patient. *J Thorac Cardiovasc Surg*. 1990;99:35-40.
3. Glenn WL, Hogan JF, Loke JS, Ciesielski TE, Phelps ML, Rowedder R. Ventilatory support by pacing of the conditioned diaphragm in quadriplegia. *N Engl J Med*. 1984;310:1150-5.
4. Glenn WL, Hogan JF, Phelps ML. Ventilatory support of the quadriplegic patient with respiratory paralysis by diaphragmatic pacing. *Surg Clin North Am*. 1980;60:1055-78.
5. Dobelle WH. Use of breathing pacemakers to suppress intractable hiccups of up to thirteen years duration. *ASAIO J*. 1999;45:524-5.